

## **Trichobezoar with Gastric Perforation: A Case Report**

**Jamal S. Kamal, FRCS (I), FACS**

*Department of Surgery, Division of Pediatric Surgery  
Faculty of Medicine, King Abdulaziz University  
Jeddah, Saudi Arabia  
drjamalkamal@yahoo.com*

*Abstract.* Trichobezoar is a rare disorder in which a collection of swallowed hair and some undigested food particles are retained in the gastrointestinal tract. It is frequently seen in psychic patients (trichotillomania). It may be present with vague symptoms, such as anorexia, anemia, weight loss and recurrent abdominal pain, or symptoms and signs of intestinal obstruction. This report illustrates a case of trichobezoar with a serious sequence and unusual presentation. In this investigation; a female child (12-years-old) with a huge trichobezoar was presented to our emergency department with diffuse peritonitis due to gastric perforation. She was treated successfully by gastrotomy and the unblock evacuation of the trichobezoar.

*Keywords:* Trichobezoar, Acute abdominal pain.

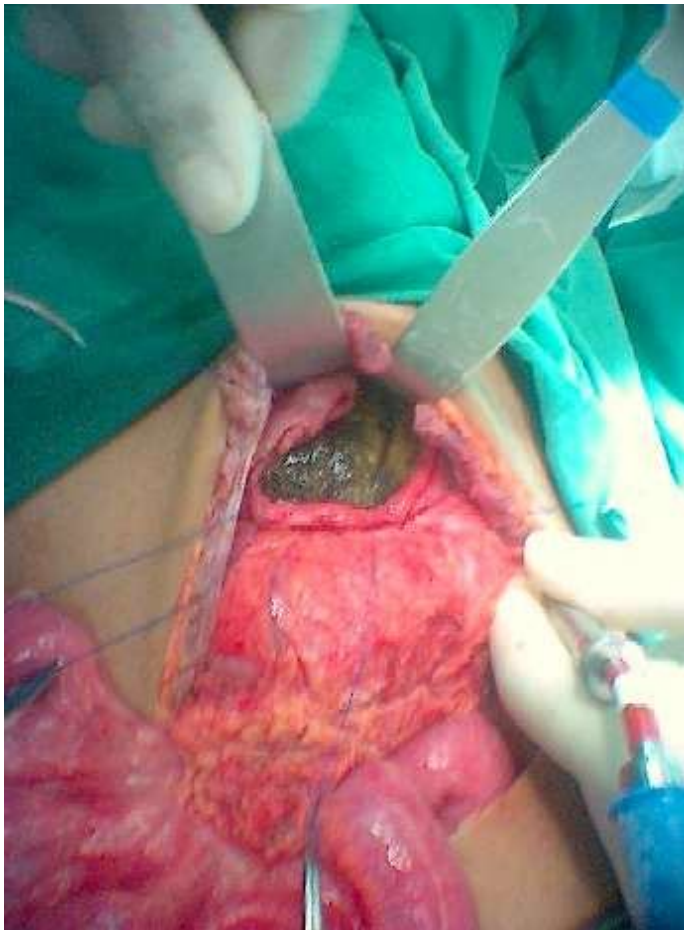
### **Case Report**

A 12-years-old Saudi girl was admitted to the Emergency Department with a sudden onset of severe abdominal pain and difficulty in breathing, clinical examination revealed; respiratory rate of 26/min, pulse 80/min, BP 100/60 and a temperature of 38.2°C. Her abdomen was tense, rigid and severely tender all over with moderate distention. Abdominal X-ray showed free peritoneal gas and diffused, with a mottled opacity in the

---

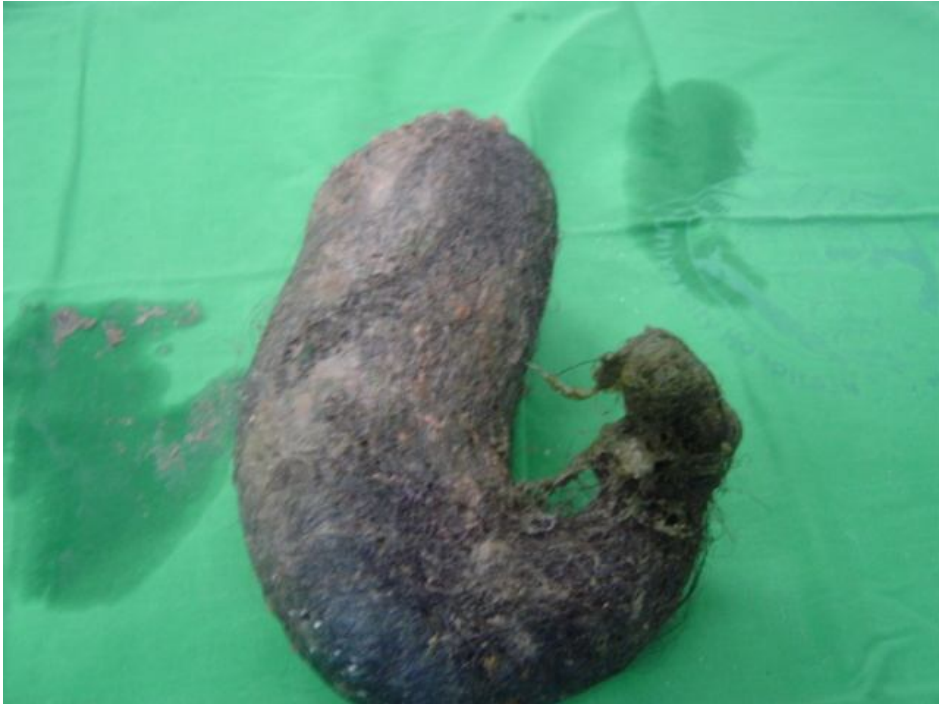Correspondence & reprint request to: Dr. Jamal S. Kamal  
P.O. Box 80215, Jeddah 2158, Saudi Arabia  
Accepted for publication: 14 June 2008. Received: 05 May 2008.

middle. In her history, she came twice to the Emergency Room in the last few days with a mild abdominal pain; diagnosed as colic, given some analgesics and sent home; no other positive findings were mentioned. She was administered with IV fluids and broad-spectrum antibiotics. After stabilization of an emergency laparotomy was done, a large amount of clear fluid was aspirated, a greater omentum was found adherent to the body of the stomach. The stomach was full by a pliable soft mass from the fundus to the pylorus. After careful release of the omentum, a tuft of dark hair was seen protruding from a small perforation in the body of the stomach, midway between the greater and lesser curvature, the site of perforation was extended as seen in Fig. 1.



**Fig. 1.** Trichobezoar emerging from the site of perforation after partial extension.

A huge trichobezoar cast the whole stomach with tail extension to the pylorus and first part of the duodenum. It was evacuated completely intact (Fig. 2).



**Fig. 2. Full-size trichobezoar after complete evacuation.**

The diameter of removed trichobezoar was  $38 \times 16 \times 8$  cm. Post operatively, the child had smooth recovery and discharged a week later.

### **Discussion**

Due to its indigestible and slippery nature, the swallowed hair seen in trichotillomania patient failed to be propelled; it may had accumulated over a period of time to form a ball of hair. The trichobezoar may had reached a large size occupying the whole stomach and extended further down to the small and/or even the large bowel (Rapunzel syndrome)<sup>[1,2]</sup>. The clinical presentation of trichobezoar varies from non-specific symptoms like; anorexia, anemia, weight loss, gastrointestinal bleeding and recurrent abdominal pain to a more serious presentation as intestinal

obstruction and perforation<sup>[3-5]</sup>. Once diagnosed, it needs to be evacuated to avoid these complications<sup>[6]</sup>.

Removing trichobezoar depends on its size. The use of Prokinetic agents to enhance its clearance was reported, but large sizes require piecemeal endoscopic removal or operative evacuation<sup>[7,8]</sup>. Successful removal of trichobezoars *via* Laparoscopic gastrotomy was reported in few cases<sup>[9,10]</sup>. Large sizes trichobezoars are more frequently present with intestinal obstruction; however, perforation particularly in the stomach is rarely seen<sup>[11]</sup>.

During examinations, I came across with only three cases of trichobezoars that were presented with gastric perforation, all cases were females and all were managed by surgical removal via laparotomy, gastrotomy and complete evacuation (Table 1)<sup>[12-14]</sup>. This case study may possibly be the fourth one in the literature to be reported and may be the first case in Saudi literature. Although, this case was successfully managed, this fatal complication could have been avoided if detected earlier. This huge trichobezoar definitely gave rise to a palpable abdominal mass, which was overlooked during her initial presentation to the emergency room. Additionally, she could have been examined through other nonspecific symptoms over an extended period and a routine investigation, like abdominal ultrasonography, would have diagnosed the trichobezoar<sup>[15]</sup>.

**Table 1. Reported cases of gastric perforation due to trichobezoar.**

Author/s	Medical centre	Age	Sex
Pul, N and Pul, M	Edirne, Turkey	13 Y	F
Jiledar, Singh G and Mitra S	Chandigarh, India	10 Y	F
Koc, O <i>et al.</i>	Nazili, Turkey	14 Y	F
Kamal, J	Jeddah, KSA	12 Y	F

The objective of this case report is to draw attention to other causes of peritonitis and the rare, but serious complication of trichobezoar; and to inform the essence in enhancing the proper and adequate clinical examination to those children presented with abdominal pain; preferably provided by a senior attendant.

## References

- [1] **Phillips MR, Zaheer S, Drugas GT.** Gastric trichobezoar: case report and literature review. *Mayo Clin Proc* 1998; **73**(7): 653-656.
- [2] **Rabie ME, Arishi AR, Khan A, Ageely H, Seif El-Nasr GA, Fagihi M.** Rapunzel syndrome: the unsuspected culprit. *World J Gastroenterol* 2008; **14**(7): 1141-1143.
- [3] **Alam M, Khan D.** An anemic patient who presented with abdominal pain due to trichobezoar; *Saudi Med J* 2002; **23**(9): 1139-1140.
- [4] **Lynch KA, Feola PG, Guenther E.** Gastric trichobezoar: an important cause of abdominal pain presenting to the pediatric emergency department. *Pediatr Emerg Care* 2003; **19**(5): 343-347.
- [5] **Al-Skaini MS, Seleem MI.** Trichobezoar: a rare cause of acute bowel obstruction. *Saudi Med J* 2000; **21**(6): 585-586.
- [6] **Sciumè C, Geraci G, Pisello F, Li Volsi F, Facella T, Mortillaro M, Modica G.** Gastric foreign body: bezoars. Apropos of two cases. *Ann Ital Chir* 2004; **75**(4): 479-482.
- [7] **Harikumar R, Kumar S, Kumar B, Balakrishnan V.** Rapunzel syndrome: a case report and review of literature. *Trop Gastroenterol* 2007; **28**(1): 37-38.
- [8] **De Backer A, Van Nooten V, Vandenplas Y.** Huge gastric trichobezoar in a 10-year-old girl: case report with emphasis on endoscopy in diagnosis and therapy. *J Pediatr Gastroenterol Nutr* 1999; **28**(5): 513-515.
- [9] **Song KY, Choi BJ, Kim SN, Park CH.** Laparoscopic removal of gastric bezoar. *Surg Laparosc Endosc Percutan Tech* 2007; **17**(1): 42-44.
- [10] **Shami SB, Jararaa AA, Hamade A, Ammori BJ.** Laparoscopic removal of a huge gastric trichobezoar in a patient with trichotillomania. *Surg Laparosc Endosc Percutan Tech* 2007; **17**(3): 197-200.
- [11] **Ventura DE, Herbella FA, Schettini ST, Delmonte C.** Rapunzel syndrome with a fatal outcome in a neglected child. *J Pediatr Surg* 2005; **40**(10): 1665-1667.
- [12] **Koç O, Yıldız FD, Nareç A, Sen TA.** An unusual cause of gastric perforation in childhood: trichobezoar (Rapunzel syndrome). *A case report. Eur J Pediatr* 2008; **168**(4): 495-497.
- [13] **Pul N, Pul M.** The Rapunzel Syndrome (trichobezoar) causing gastric perforation in a child – a case report. *Eur J Pediatr* 1996; **155**(1): 18-19.
- [14] **Jiledar, Singh G, Mitra S.** Gastric perforation secondary to recurrent trichobezoar. *Indian J Pediatr* 1996; **63**(5): 689-691.
- [15] **Sharma UK, Sharma Y, Chhetri RK, Makaju RK, Chapagain S, Shrestha R.** Epigastric mass in a young girl: trichobezoar. Imaging diagnosis. *Nepal Med Coll J* 2006; **8**(3): 211-212.

كتلة من الشعر متجمعة، تسببت في حدوث ثقب في المعدة:

تقرير عن حالة

جمال صديق كمال

قسم الجراحة، كلية الطب، جامعة الملك عبدالعزيز

جدة ، المملكة العربية السعودية

المستلخص. إن تجمع كتلة أو كتل من الشعر وبقايا بعض الأطعمة في الجهاز الهضمي من الأشياء غير المألوفة، وتتكون نتيجة البلع المتكرر للشعر، وغالبًا ما تحدث عند من يعانون من بعض الاضطرابات النفسية. ومن الأعراض المصاحبة لها، آلام البطن المتكررة، فقدان الشهية للأكل، نقص الوزن وأعراض فقر الدم إلا أنه عندما يكون الحجم كبيرًا قد يؤدي إلى الانسداد المعوي. في هذا التقرير نستعرض حالة طفلة تبلغ من العمر ١٢ عامًا تم علاجها بمستشفى الجامعة، وكانت تعاني من آلام حادة في البطن نتيجة ثقب في المعدة، حدث بسبب وجود كتلة كبيرة من الشعر المتجمع في المعدة. وتعتبر من المضاعفات الخطيرة والنادر حصولها في مثل هذه الحالات.